

# The Evolution of Esthetic Dental Materials

The range of restorative options available to dentists has changed dramatically over the past 30 years.

By Michael R. Sesemann, DDS

In 1981, the materials decisions to be made by a newly minted dentist were very different than they are today. After the selection of a local laboratory to handle the indirect restorations that are part of the “crown-and-bridge” aspect of practice, the major material decision for many clinicians involved choosing a semi-precious alloy for porcelain-fused-to-metal (PFM) restorations. Materials for direct restorations included plastic jars of amalgam capsules and a box of composite technology that involved mixing together paste A and B and getting it into the preparation before it could set.

Shades and layering were unheard of at the time. There was only the “universal shade” used for 75% of the anterior restorations performed. For bonding, a bottle of weak liquid acid for enamel conditioning and a chemical-set clear methacrylate-based resin completed the restorative armamentaria.

Of course, patient expectations were different, too. Even so, in reflecting on the history and evolution of the materials used 30 ago, it is astounding to ponder how far dentistry has come and the range of restorative options dentists today can offer their patients.

## Direct Restorations

Acrylic resins replaced silicate cements in the middle of the 20<sup>th</sup> century as the only esthetic material in dentistry.<sup>1</sup> However, due to dependence on properties that could only be delivered with adequate bonding concepts that had not yet been discovered, the benefits of such an evolution were minimal at best.<sup>2</sup> Advancements in bonding technology would go hand in hand with the success of acrylic resins.

In the 1970s, composites emerged to replace acrylic resin, but the particles were very large, resulting in difficult polishing and surface roughness

as the large particles were “plucked” from the resin matrix. To combat these unwanted properties, the first micro-fill composites were developed in the 1980s.<sup>3</sup> Although this class of composites polished well, chipping and bulk fracture limited their use in high stress-bearing areas.<sup>4</sup>

In the 1990s, a synergy of composite and bonding technology began to advance composite use. There was greater understanding of the importance of the particles in the resin matrix. Beginning with microhybrids, the nature of the particle content was manipulated in terms of particle shape, load, size, and

chemical makeup.<sup>5</sup> Diffraction capability began to be differentiated, and techniques to layer different composite compositions to mimic the nuances of natural tooth structure came into being.<sup>6,7</sup>

Currently, as a result of the development of nanotechnology, we find ourselves surrounded by many materials with excellent handling capabilities, great durability, enhanced bonding capacities, less shrinkage, improved polishing, and highly esthetic optical effects. Indeed, with the variety of shades, translucencies, opacities, refraction indices, and effects available today, clinicians are closer than ever before to having the ability to construct direct restorations that have the optical metamersisms of the natural dentition (Figure 1 through Figure 6).<sup>8</sup>



In order to perform dental procedures that demonstrate a responsible esthetics

For product information on composite materials, visit:

[dentalaegis.com/go/id47](http://dentalaegis.com/go/id47)  
[dentalaegis.com/go/id48](http://dentalaegis.com/go/id48)

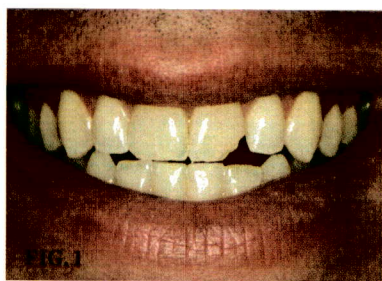

FIG. 1

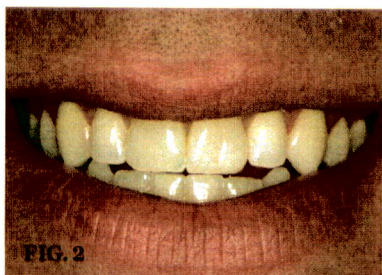


FIG. 2

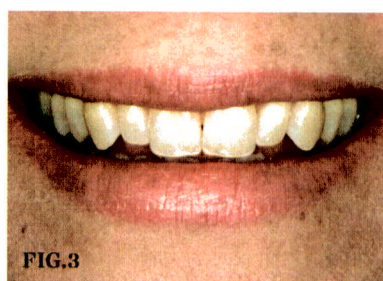

FIG. 3

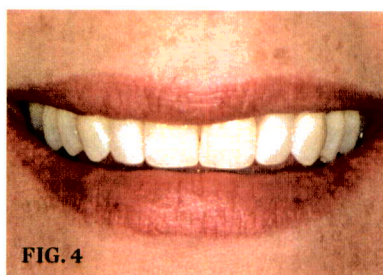


FIG. 4

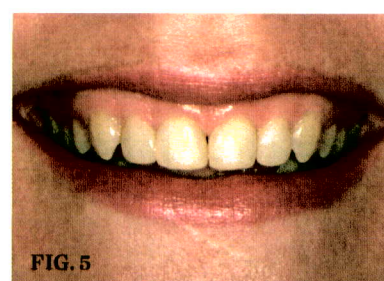


FIG. 5

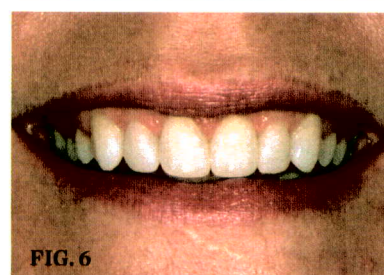

FIG. 6

**CENTRAL INCISOR FRACTURE (1.)** Tooth fracture of the maxillary left central incisor. **(2.)** Fracture of the central incisor conservatively restored with composite restorative material (Empress Direct; Ivoclar Vivadent).

**SMALL LATERAL INCISORS (3.)** The patient was unhappy with the appearance of her diminutive maxillary lateral incisors. **(4.)** Composite was used to add bulk and contour to diminutive lateral incisors without any preparation (4 Seasons<sup>®</sup>; Ivoclar Vivadent).

**RESTORATION REPLACEMENT (5.)** Composite bonding of teeth Nos. 7 to 10 completed by the author in 1988 needed replacement after 18 years. **(6.)** No-preparation bonding of teeth Nos. 6 to 11 after crown lengthening to allow proper proportionality of the maxillary anterior sextant (Empress Direct).



**MICHAEL R. SESEMMAN, DDS**  
Private Practice  
Omaha, Nebraska

Clinical Instructor  
Kois Center for Advanced  
Dental Education  
Seattle, Washington



doctrine reflecting the principles of conservation of tooth structure,<sup>9</sup> it is imperative that clinicians develop and exercise modern-day techniques that incorporate expertise and skills in composite artistry. A nano-particle or microhybrid direct composite can fulfill the needs for anterior bonding and restorations, as well as posterior applications. The most important factor is clinicians' knowledge of the nuances of the material they are working with so they can master techniques to satisfy restorative and esthetic objectives.<sup>10</sup>



For product information on adhesive/bonding materials, visit:

[dentalaegis.com/go/id49](http://dentalaegis.com/go/id49)

### Indirect Restorations

The evolution of indirect porcelain technology occurred at a fairly methodical pace until it coincided with an aging generation of baby boomers who wanted to retain a youthful, esthetic smile. A demanding public greatly accelerated the rate of development, beginning in the mid-1990s, as the dental profession sought a bio-identical restoration that

could mimic the optical metamerisms of natural teeth.

The use of ceramic materials in dentistry began in the late 18<sup>th</sup> century when dental professionals discovered that the porcelain used to fabricate denture teeth could be hollowed out and secured to natural teeth to create porcelain jacket crowns. Although porcelain (ie, all-ceramic) jacket crowns demonstrated a level of previously unattainable esthetics, the lack of strength (50 MPa) that led to chipping, fracture, and clinical failure made routine implementation impossible.

Those same clinical failure characteristics have plagued various evolutions in the quest for an acceptable indirect esthetic restoration. For that reason, PFM restorations remained a popular choice for some time, especially when the metric for success was weighted toward strength and durability.<sup>11</sup> However, it is easily illustrated that using PFMs in the esthetic zone presents its own disadvantages by not allowing certain light characteristics, such as translucency and diffraction, to occur (Figure 7 and Figure 8).

The search for the ideal esthetic indirect restorative material has undergone

many permutations. Although knowledge of ceramic history is important in order for clinicians to make informed decisions about what their clinical offerings will be, it is equally important for practitioners to be able to provide their patients with a variety of indirect alternatives that are tailor-made for any given situation. The 21<sup>st</sup> century restorative team must decide on a material choice by determining the relative importance of a number of factors, including strength, conservatism, and esthetics.

It is important for dental providers to be able to diagnose and provide restorations composed of different substrates to suit a given set of presenting conditions. Anterior esthetics is a driving force in dentistry today. For conservatism, interdisciplinary care that includes orthodontics followed by no-preparation or minimum-preparation veneers is tremendously valuable for the patient. Therefore, a command of working with feldspathic porcelain has distinct advantages (Figure 9 and Figure 10).<sup>12</sup> When there is a demand for increased restoration thickness, a stronger substrate can be leucite-reinforced (eg, IPS Empress<sup>®</sup>, Ivoclar Vivadent, [www.ivoclarvivadent.com](http://www.ivoclarvivadent.com); Authentic<sup>®</sup>, Jensen Dental, [www.jensendental.com](http://www.jensendental.com)) (Figure 11 and Figure 12) and lithium disilicate (eg, IPS e.max<sup>®</sup>, Ivoclar Vivadent). When even more restoration thickness must be provided, there are high-strength tooth-colored cores such as yttrium-stabilized zirconium dioxide to support layering porcelains that mimic enamel. There are also times when presenting conditions require the mixing of restorative media to solve different dilemmas (Figure 13 through Figure 16).

**“Responsible esthetics can only derive from a relentless commitment ... to not only provide a restoration that looks natural, but also respects the sanctity of the remaining natural tooth structure.”**

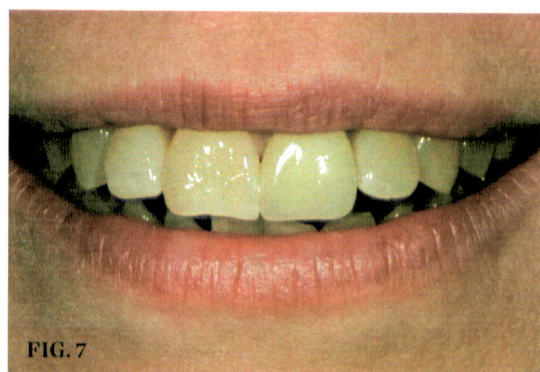


FIG. 7

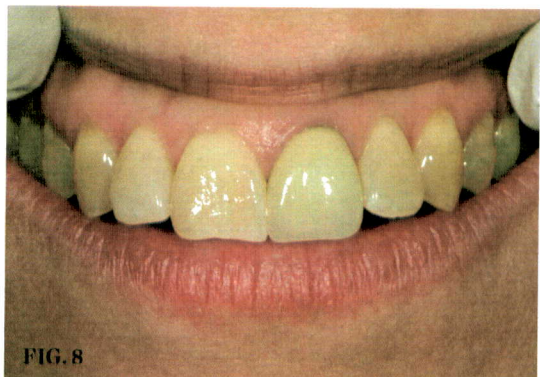


FIG. 8

**LOW LIP DYNAMICS (7.)** This patient with low lip dynamics has been happy for 25 years with this anterior PFM restoration. **(8.)** Upon lip retraction, it is clear that this PFM would not be appropriate for a patient with high lip dynamics.

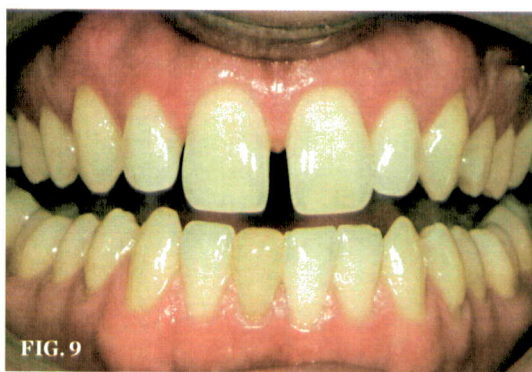

FIG. 9

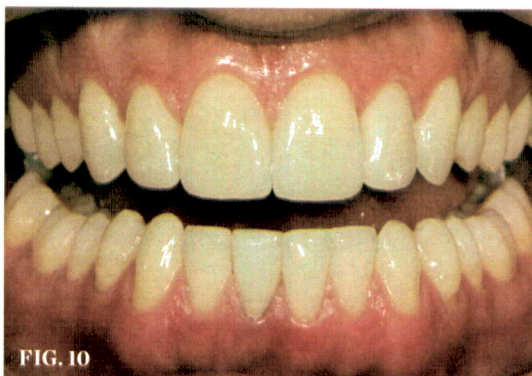


FIG. 10

**CLOSING A DIASTEMA (9.)** This patient sought a restorative solution that could eliminate the diastema and lighten teeth. **(10.)** Full-mouth bleaching, minimal preparation feldspathic veneers on teeth Nos. 6 to 11, and a leucite-reinforced restoration on tooth No. 25 fulfilled the patient's objectives.

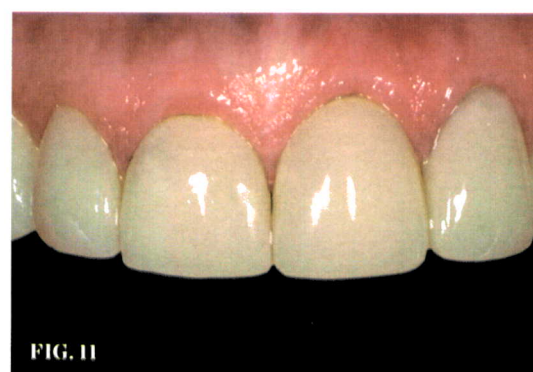


FIG. 11

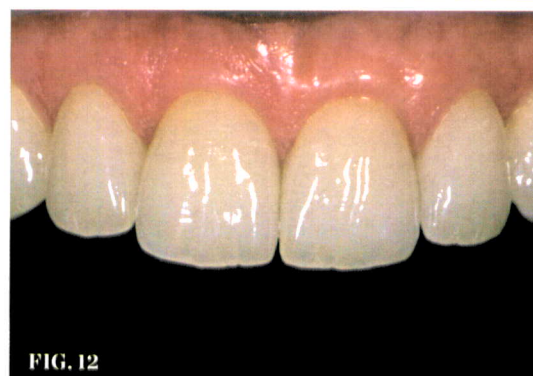

FIG. 12

**PORCELAIN VENEER REPLACEMENT (11.)** Porcelain veneers from 1989 presented for replacement in 1996. **(12.)** A combination of periodontal crown-lengthening procedures and restorative treatment with layered Empress veneers created a more natural appearance.



There should be no “one size fits all” mentality when diagnosing and treating individual cases. Responsible esthetics<sup>9</sup> can only derive from a relentless commitment on behalf of the clinician and laboratory technician to not only provide a restoration that looks natural, but that also respects the sanctity of the remaining natural tooth structure in the process.

Drawing upon the successes and failures of prior attempts to create a clinically successful all-porcelain crown, lithium disilicate was introduced in various manifestations, including a monolithic form that demonstrates strength of 400 MPa. Because of its composition, lithium disilicate can be either adhesively or cohesively retained. This versatility can be used in the anterior or posterior areas of the oral cavity, and allows creativity in preparation design to facilitate conservation of tooth structure.



To read more about the material science for cosmetic dentistry, visit:

[dentalaegis.com/go/id45](http://dentalaegis.com/go/id45)  
[dentalaegis.com/go/id46](http://dentalaegis.com/go/id46)

## Bonding Technology

As stated previously, a number of the direct and indirect innovations could not have occurred without the concurrent evolution of bonding concepts. Beginning with the earlier work of Buonocore,<sup>13</sup> to the classic papers of Nakabayashi<sup>14</sup> in 1982 and Fusuyama<sup>15</sup> 2 years earlier on dentin bonding, it was absolutely necessary for material evolutions and technique innovation to become synergistically linked. Adhesive dentistry was not really demanded prior to the advancement of metal-free restorations and the advent of conservative dentistry. Their union was critical for complete use of modern all-ceramic materials.

The dental office of the 21<sup>st</sup> century is best served when clinicians understand total-etch and self-etch protocols and where each can be applied when they are the best solution for a specific situation.<sup>16</sup> The success or failure of the restoration is largely due to completion of the appropriate technique by the clinical team. In addition, it is becoming apparent that there are additional steps that can be included in bonding protocols to extend the longevity of the bond.

For example, including chlorhexidene gluconate and/or benzalkonium chloride in protocols can curtail initiation of matrix metalloproteinases to inhibit their ability to eat away at the hybrid layer over time.

## Conclusion

Dentists today are indebted to dental researchers and their corporate partners for providing a vast array of products that can now be used in their practices. The manner in which dentists practice today compared to 30 years ago has been profoundly affected by the evolution of the material options available. In less than a generation of dental science, the materials used today are literally light years from where they were in 1981. Although the number of options requires knowledge and strict due diligence by the restorative team before they can be applied in practice, this is a small price to pay for the variety of restorative solutions now at the disposal of practicing clinicians.

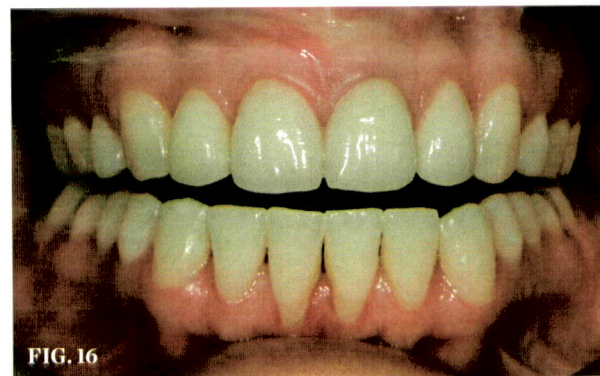
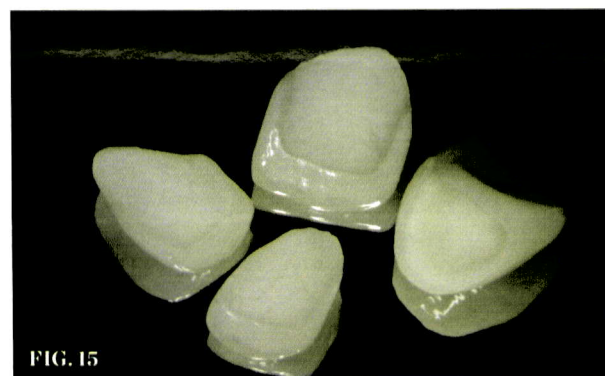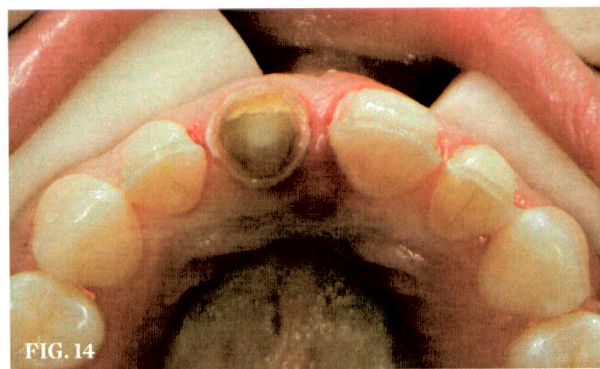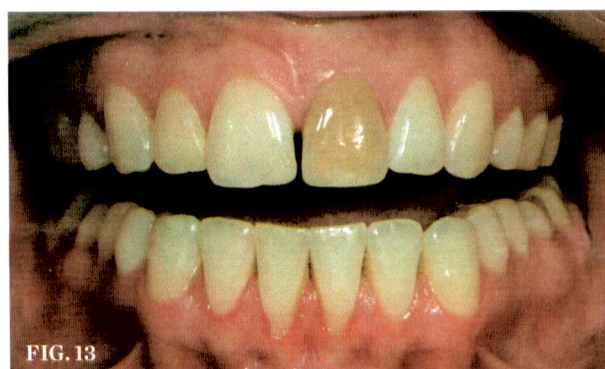## Acknowledgments

The author would like to express his sincere gratitude to the laboratory technicians who

contributed to this article by providing dental restorations of the highest quality: Lee Culp, CDT; Bradford Patrick, CDT; Nelson Rego, CDT; and Juan Rego, CDT.

## References

- Hervás-García A, Martínez-Lozano MA, Cabanas-Vila JC, et al. Composite resins. A review of the materials and clinical indications. *Med Oral Patol Oral Cir Bucal*. 2006;11(2):E215-220.
- Milnar FJ. The evolution of direct composites. *Compend Contin Educ Dent*. 2011;32(1):80-81.
- Sensi LG, Strassler HE, Webley W. Direct composite resins. *Inside Dentistry*. 2007;3(7):76.
- Kugel G, Perry R. Direct composite resins: an update. *Compend Contin Educ Dent*. 2002;23(7):593-608.
- Fortin DE, Vargas MA. The spectrum of composites: new techniques and materials. *J Am Dent Assoc*. 2000;131(suppl):26S-30S.
- Dietchi D. Layering concepts in anterior composite restorations. *J Adhes Dent*. 2001;3(1):71-80.
- Magne P, Holz J. Stratification of composite restorations: systemic and durable replication of natural aesthetics. *Pract Periodontics Aesthet Dent*. 1996;8(1):61-68.
- Villarreal M, Fahl N, Maria de Sousa A, et al. Direct esthetic restorations based on translucency and opacity of composite resins. *J Esthet Restor Dent*. 2011;23(2):73-88.
- Sesemann MR. Of dreams, milestones and responsibilities. President's Address to the American Academy of Cosmetic Dentistry (reprint of speech). *J Cos Dent*. 2009;25(2):8.
- Ritter AV. Direct resin-based composites: current recommendations for optimal clinical results. *Compend Contin Educ Dent*. 2005;26(7):481-527.
- Marra LM. An historical review of full coverage of the natural dentition. *NY State Dent J*. 1970;36(3):147-151.
- Calamia JR. Etched porcelain veneers: the current state of the art. *Quintessence Int*. 1985;16(1):5-12.
- Buonocore MG. A simple method of increasing the adhesion of acrylic filling materials to enamel surfaces. *J Dent Res*. 1955;34(6):849-853.
- Nakabayashi N, Kojima K, Masuhara E. The promotion of adhesion by the infiltration of monomers into tooth substrates. *J Biomed Mater Res*. 1982;16(3):265-273.
- Fusuyama T. *New Concepts in Operative Dentistry*. Chicago, Illinois: Quintessence Publishing Co. Inc; 1980.
- Swift EJ, Perdigão J, Heymann HO. Bonding to enamel and dentin: a brief history and state of the art, 1995. *Quintessence Int*. 1995;26(2):95-110.



**CASE EXAMPLE (13.)** This patient presented with an extremely discolored tooth No. 9 and a midline diastema. **(14.)** Occlusal view of preparation illustrates the different approach in preparation for tooth No. 9 vs. teeth Nos. 7, 8, and 10. **(15.)** Prosthodontic units consisting of a zirconia core restoration for tooth No. 9 and conservative leucite-reinforced (Empress) veneers for teeth Nos. 7, 8, and 10 were fabricated. **(16.)** Retracted view (1:2 magnification) of the treated case illustrates the successful mixing of different restorative media.