



# MAPPING THE COURSE

## Treatment Planning and Decision-Making in Implant Dentistry

---

In the ongoing search for an esthetic smile, patients are increasingly seeking implants as a treatment solution. As a result, more and more general dentists are incorporating implant dentistry into their practices. Because more complex implant cases require a multidisciplinary approach involving collaboration among the restorative dentist, the surgeon, and the laboratory technician, correct assessment and proper treatment planning from the outset of the process is critical to successful outcomes. Inside Dentistry examines ways that general practitioners are approaching implantology, whether alone or in collaboration, including technological, procedural, and material considerations for treatment planning, as well as the adoption of prosthodontically-driven implant placement protocols.

---

**I**n implant prosthodontic treatment today, patients are presenting with a wide range of needs. On one side of the spectrum are relatively easy treatment solutions, such as single tooth replacements in favorable environments, which can be completed by general practitioners with the right education and experiences. On the other side of the spectrum are complex, interdisciplinary treatment solutions that demand the combined expertise of both the surgical and prosthodontic disciplines.

“In between these extremes are a number of treatment solutions for which the primary determinants of who is involved in performing the treatment depends upon what is needed and the expertise of the practitioner or practitioners to optimize the treatment solution required,” explains Michael R. Sesemann, DDS, a private practitioner in Omaha, Nebraska, and an adjunct faculty member at the Kois Center. “It is up to the primary patient contact to determine how a case’s treatment should be undertaken responsibly.”

“Some cases are not difficult and rather predictable for general dentists, including those in which there is adequate mesiodistal space between adjacent teeth, adequate buccal-lingual thickness, and no major anatomical concerns, such as those involving nerves, artery bundles, or concavity in the bone,” says Ankur Gupta, a general dental practitioner in North Ridgeville, Ohio, who has been placing and restoring implants for 7 of his 11 years in practice. However, he cautions that not all cases are simple, especially when general dentists are first beginning to

By Allison M. DiMatteo, MPS

**“There are definitely times when the combined treatment expertise and clinical application of both the surgeon and the restorative dentist is the best option. That determination is usually made by the treating dentist who has the relationship with the patient.”**



provide implant treatments. “If there is a sliver of doubt, they should refer out.”

“Each practitioner will individually set the conditions requiring referral in his or her practice,” Sesemann says. “Currently, I would much rather have an interdisciplinary team approach for full-arch implant placement, sinus lift procedures, extremely deficient alveolar ridges requiring sophisticated grafting, and times when the patient requests IV sedation, which I do not do in my office.”

Sesemann adds that there are definitely times when the combined treatment expertise and clinical application of both the surgeon and the restorative dentist is the best option. That determination is usually made by the treating dentist who has the relationship with the patient.

“I believe that implant dentistry is all about teamwork, or what I refer to as the ‘Pyramid of Implant Success,’” says Chad C. Duplantis, DDS, a general practitioner in Fort Worth, Texas, who restores dental implants. “It is a collaboration among the restorative dentist, whose goal is to restore function, form, and

esthetics; the surgeon, whose goal is to place the implants safely and efficiently; and the laboratory technician, who shares the same goals as the dentist—all with a patient-centered focus. Everyone is equally important.”

### Navigate the Technology

Among the tools available to make the procedures associated with implant placement and restoration more predictable and accurate is cone-beam computed tomography (CBCT), which has revolutionized the evaluation of implant sites pre- and postoperatively in three dimensions (3D), observes Gary Orentlicher, DMD, a private practitioner at New York Oral, Maxillofacial, and Implant Surgery in Scarsdale, New York, and Chief of Oral and Maxillofacial Surgery at White Plains Hospital Center. Although the argument could be made to use CBCT technology on all dental implant patients, the additional radiation, although relatively low, precludes that. Most dental implants are still placed using information from

conventional periapical or panoramic radiographs, but CBCT is being used more every day. Orentlicher says it will soon become the most common radiologic modality to evaluate an implant surgical site.

CBCT data can be digitally evaluated using proprietary software produced by many dental implant and software manufacturers. By importing CBCT data into such software, clinicians not only have the ability to evaluate the bone in the surgical site, but also to plan the accurate position, ideal length, and diameters of implants based on the planned restoration—all through digital processes, Orentlicher explains. If taken to the next step, surgical guides can be fabricated to aid in making accurate osteotomies and accurately placing the implants according to a digital treatment plan.

“The fallacy in thinking regarding guided implant placement is that it’s an easier way to place a dental implant. It’s not; it’s a more accurate way,” Orentlicher emphasizes. “Guided surgery workflows and techniques aid the clinician in placing implants more accurately and predictably, while avoiding vital anatomy, according to a treatment plan that’s restoratively driven.”

Guided surgery workflows are essentially planning dental implants using reverse engineering, he says. The final restoration is planned first, and then the implant is planned optimally according to that restorative plan, thus maximizing patient treatment outcomes. Workflows and software are available that will allow dentists to fabricate their own surgical guides. Some have relatively simple workflows, while others are more complex, Orentlicher says.

“Guided surgery is extremely useful to dental technicians on many levels,” explains Bill Marais, RDT, owner of Disa Dental Studio in Portland, Oregon. With screw-retained restorations, for example, dental technicians must align the access holes with the design of the implant restorations being fabricated to avoid compromising esthetics and strength. Compromised implant placement leaves the technician’s hands tied, requiring him or her to spend time making a restoration work, rather than focusing on esthetics.

“If surgical guides are fabricated correctly using the proper protocol, it does not matter whether a laboratory or the dentist creates them,” Marais says.

Other technologies that have opened avenues of improved and more efficient implant treatment are optical intraoral scanners. Optical intraoral scanners enable importing of accurate patient clinical data into planning software, fabricating 3D printed models, imaging implant "scan bodies," and planning and fabricating provisional and definitive implant restorations, Orentlicher says.

"If you are just getting started with dental implants and are placing 10 to 15 a year, it would be quite a stretch to invest in a CBCT machine, a digital scanner, and a milling unit for a surgical stent," Gupta suggests, adding that a periapical image and thorough planning can be sufficient for non-complex cases where the risks are very low. "However, if you did invest in those technologies, you would eliminate a great deal of risk, both surgically and restoratively, because they would help you determine the ideal implant size, location, angle, and other considerations."

Orentlicher advises doctors to investigate the literature regarding the proven science and accuracy behind claims made by some

manufacturers. Patient case volume, equipment purchases, and the cost-effectiveness of these technologies are significant factors in deciding whether to use them, he adds.

Colin Richman DMD, a periodontist practitioner in Roswell, Georgia, and a faculty member in the Department of Graduate Periodontics at the College of Dentistry, Augusta University, asserts that both conventional and/or digital treatment planning tools are needed to establish an accurate diagnosis and subsequent treatment plan for the patient. These tools include comprehensive radiographs, including a CBCT to understand and diagnose the overall health of the mouth for existing disease entities such as periodontitis and caries; mounted dental casts (impressions or virtual) to understand the patients occlusion; comprehensive photographs to understand and record soft tissue morphology; and comprehensive medical and dental records to understand historical factors that will impact the treatment plan and future prognosis of the case. Armed with these records, interdisciplinary team members should collaborate during the treatment

planning session and develop a treatment plan that will be functional, esthetic, and predictable for long-term success.

"These comprehensive diagnostic tools are essential to help render the patient completely free of oral disease prior to installing dental implants," Richman contends. He explains that patients who have lost teeth from periodontal disease are three times more susceptible to peri-implant disease and implant loss than patients who have lost teeth due to caries. "Therefore, inadequate treatment of existing oral pathology prior to implant placement might," he says, "be a risk factor associated with the increasing incidence of peri-implantitis noted in practice today."

### Get a Bearing on Site Preparation

The optimal dental implant site is one in which there is adequate bone and soft-tissue volume to place and support an implant and have it successfully osseointegrate in a position in which a functional and esthetic restoration can be made with minimal difficulty. According to

**sani-soak** *ultra*  
 www.enzymeindustries.com • (888)236-9963 Anti-Corrosive Enzymatic Cleaner

**BEFORE** **AFTER**

THE DENTAL ADVISOR  
 2016 PREFERRED

THE DENTAL ADVISOR  
 2017 PREFERRED PRODUCT

**SEE WHAT YOUR COLLEAGUES ARE SAYING ABOUT SANI-SOAK ULTRA!**

"I was so delighted to see the amazing results of Sani-Soak Ultra on our high quality Hu-Friedy instruments that we invested in more than 10 years ago. We take great pride in our work and this includes having instruments that are absolutely beautiful. Sani-Soak Ultra is not only cost effective, but has our instruments looking brand new again. It is the best that I have ever seen and used." - Charlene Castro, D.D.S. • Cerritos, CA

**Tired of Stained Uniforms?**

**BLOOD BUSTER**

**Removes Organic Stains and Odors!**

Blood Buster removes blood, saliva, vomit, wine, coffee and other people and pet accidents from clothing, carpet and upholstery.

www.enzymeindustries.com (888) 236-9963

(Circle 24 on Reader Service Card)

*inPractice*<sup>®</sup>

Digital Dental Manufacturing Solutions

*inPractice* OPEN digital dental manufacturing solutions for clinicians is quickly setting new standards in digital dentistry.

*inPractice* solutions are based on an adaptable digital platform which includes our exclusive enhancements, providing you with technology that will serve your needs both now and in the future. This OPEN platform provides you freedom to choose material, scanning, and software solutions that best fit your practice.

We've put our 40 years of manufacturing experience into developing our *inPractice* products, services and training programs so you can quickly transition your practice to the digital world.

Our offerings provide the full-spectrum of digital dental manufacturing solutions to manage all types of hard and soft materials, from single restorations to quadrant dentistry – even full-arch prosthesis, implant abutments and bars.



DECREASE CHAIR TIME • ELIMINATE  
DO-OVERS & RE-VISITS • DELIGHT YOUR  
PATIENTS • INCREASE PROFITS

## NO LIMITS

*"Axsys' extensive manufacturing and CAD/CAM experience is unlike any other supplier or distributor of this technology - Nobody else can do what they do."*

*Dr. Khaldoun Attar, DDS  
Sun Dental and Denture*



See success stories from other doctors, view complex case examples, and access our free educational materials at [www.axsysdental.com](http://www.axsysdental.com)

(Circle 25 on Reader Service Card)

Orentlicher, although this is a common occurrence, it is sometimes not easily possible based on many factors, whether local and/or systemic.

"Less-than-ideal patient cases commonly require tissue preservation and hard and soft tissue augmentation and grafting to create an environment that will result in good long-term esthetic and functional results," Orentlicher explains. "Tissue grafting and augmentation techniques used today have allowed dentists to successfully treat some patients with dental implants that would never have been able to be treated decades ago."

Richman states that routinely after tooth loss, the facial bony wall will atrophy to a greater or lesser extent. Therefore, it is critical during treatment planning and subsequent case presentation to advise patients that not only have they lost a tooth, but they have also lost part of the supporting bone and gingiva associated with the lost tooth.

"Published studies demonstrate that a minimum thickness of 1.5 mm to 2 mm of facial and lingual bone is essential for preserving periodontal and gingival health around dental implants," Richman explains. "This supports the need for socket augmentation at the time of tooth loss to decrease the amount of ridge atrophy associated with the tooth loss. In addition, patients must be advised that supplemental hard and soft tissue grafting may be indicated in the future, either at the time of implant placement or later, depending on the clinician's assessment of the situation."

Today, hard and soft tissue augmentation is frequently and possibly almost routinely indicated at the time of implant placement, Richman says. Although many clinicians are placing a hard and/or soft tissue augmentation product at the time of implant placement to achieve the appropriate profiling to support the dental implant, he cautions that the techniques undertaken to achieve tissue augmentation at the deficient site require serious consideration, as well.

"In cases where bone quality or quantity is in question, this is a joint decision, with the surgeon playing the largest role," says Duplantis, noting that he and his surgeon always have a CBCT to refer to. "The surgeon will always consult with me, but I usually leave the decision up to him. For esthetically demanding cases, I play a greater role in the decision process because I know where I want the tissue to be."

### A Fork in the Road: Cements or Screws?

"Peri-implantitis is a complex, multimodal problem in implant dentistry," Orentlicher says. "The screw-down versus cement-retained restoration question is a constant debate in implant dentistry that has vehement supporters and opponents on both sides of the question."

Richman cites several disadvantages to cement-retained implant restorations, including a demonstrated inability to efficiently remove subgingival cement, even at 1 mm. He also notes that cement-retained restorations are difficult to remove when necessary, resulting in tremendous frustration, expense, disappointment, and other stress-inducing negatives for the restorative dentist, the surgical specialist, and especially the patient.

"With the increasing need to prevent and/or treat peri-mucositis and peri-implantitis, the ability to easily remove an implant restoration will facilitate that treatment," Richman says. "If it's a cemented restoration, it may impede the long-term quality of the treatment that is available."



# A Case Study

When engaging dental implant planning, the manner in which members of the treatment team collaborate depends on the individual case, the type of procedure(s) required (eg, extraction/immediate implant placement, extraction and grafting with delayed implant placement), and the complexity. Although the surgical and restorative approaches that team members select when treating a single implant case may differ from those undertaken when treating a full-arch implant case, clearly defined expectations, proper procedural sequencing, and interdisciplinary communication and collaboration remain the hallmarks of well-planned and executed implant treatments, explains Marco Brindis, DDS, Assistant Professor in the Department of Prosthodontics at the Louisiana State University Health Sciences Center School of Dentistry. Throughout the process, each member of the team—from dental assistants to laboratory ceramists, including the patient—plays a vital role. Here, the step-by-step team process is described for a typical, non-complex case where a patient requires a single tooth extraction and subsequent implant placement and restoration.



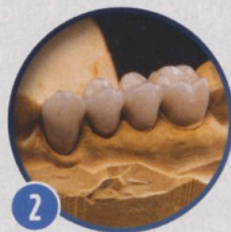## Initial Examination and Records Taking.

During the patient's first appointment, the dental assistant obtains records, including impressions, which can be either analog or digital intraoral scans. The dental assistant will also take a conventional periapical radiograph of the area for a quick diagnostic reference. A CBCT scan will also be required for analyzing bone quantity and quality as well as for the virtual planning and the surgical execution. This study can be taken either at the dental practice by the dental assistant, or at a radiology center.

The dentist performs a thorough examination to determine that the tooth is indeed hopeless and requires extraction. It is important to remember to never extract a tooth without having a plan to replace it. In this case, an emergency extraction is not required, which enables a planned extraction and implant placement. The patient's needs and expectations are assessed in

terms of tooth color, esthetics, and alignment to determine if any procedures would be required prior to extraction and implant placement (eg, tooth whitening, orthodontics).


"Equally important is establishing realistic expectations for the patient," Brindis says. "It is important to explain that a dental implant is not a tooth, but it is a great 'Plan B.' Patients also need to understand the possible complications, such as interproximal contacts that can open over time or crowns loosening from the implant."



## Diagnostic Wax-Up and Analysis.

The dentist or dental assistant then creates a digital model of the patient's intraoral condition using CAD software to begin the treatment planning process. This is accomplished using either an analog polyvinyl siloxane impression, pouring a conventional stone model and

then scanning it to convert it to a digital model (which may involve the laboratory), or a digital intraoral impression. Alternatively, the laboratory can perform the diagnostic wax-up when all records are provided.




## Prosthodontic Restoration Design and Implant Placement Planning.

Using CAD software and the digital model as a basis (or analog models and a conventional wax-up), the dentist (or laboratory) plans the restoration and otherwise draws it to indicate exactly where margins will be placed to establish the ideal emergence profile. This prosthodontic plan determines subsequent implant placement.

The dentist merges the previously obtained CBCT scans together with the digital restoration wax-up using the treatment planning software in order to plot the precise implant location and angulation. Lines and indicators are drawn through the center of the proposed restoration to indicate implant position, depth, width, etc. In more complex, multi-tooth cases, it is highly recommended to have the dental laboratory intimately involved in this process.

This combined restoration and implant placement plan enables control, evaluation, and execution of all aspects and components of treatment (ie, implant and abutment selection, surgical guide fabrication, surgery and implant placement, tissue management, and restoration fabrication).

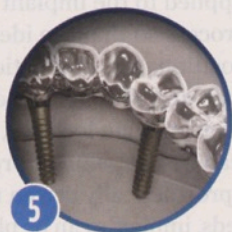


## Interdisciplinary Consultation & Collaborative Treatment Planning.

Once the prosthetic plan has been developed, the dentist (and laboratory) consults with the

oral surgeon to discuss the treatment plan and extraction/implant placement. "We discuss different techniques from a surgical perspective, in addition to developing a plan for handling any grafting needs that might arise," explains Brindis. "Even when everything looks fine restoratively, we prepare for any situation and any contingencies."

Brindis notes that upon reviewing the implant treatment plan, the surgeon may decide to refine the plan in terms of implant length and width based on an evaluation of bone quality and quantity.



### Surgical Guide Fabrication.

Once the dentist and surgeon have agreed upon the implant placement plan, the dentist can send the surgical guide/prosthetic digital file to a laboratory to fabricate the surgical guide or fabricate it in-house using 3D printing or CAM processing. The surgical guide is then forwarded to the oral surgeon for use during extraction and implant placement.

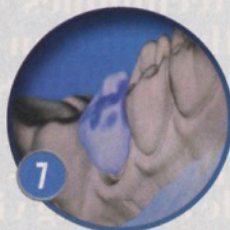

### Extraction & Implant Placement.

After tooth extraction, every step of the implant placement procedure (ie, drilling, implant placement) is fully guided through the surgical stent to ensure that the outcome most closely replicates what was treatment planned. "The surgical guide ensures optimal implant placement in three dimensions: buccal-lingually, mesial-distally, and in depth," Brindis explains.

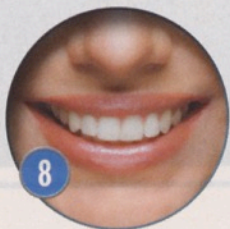If primary stability allows for it, a healing abutment is placed at the time of the implant placement. This ensures ideal tissue contours and establishes the proper emergence profile. Brindis notes, however, that it is up to the

discretion of the surgeon at the time of extraction to determine if immediate implant placement is possible. In some instances, bone and tissue grafting may be required that necessitates a second surgery for implant placement.



### Restoration Fabrication.

After healing, the dentist removes the healing abutment, places an impression coping or "scan body" for final impression taking, and then replaces the healing abutment. The dentist also takes a final shade, which, along with the impressions, is forwarded to the dental laboratory for use in fabricating the final restoration according to the implant treatment plan.



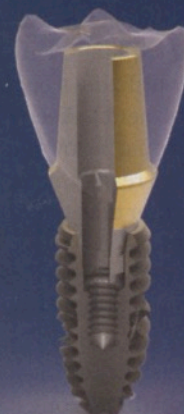### Final Restoration.

Once fabricated by the dental laboratory, the restorative dentist seats the final restoration onto the implant/abutment. Previous to final torque and delivery, the dental assistant will take a bitewing radiograph to verify proper seating of the abutment into the implant.

Although this article has demonstrated one example of a collaborative team workflow and described a few different protocols, various approaches can be followed depending on preference, clinical requirements, and other considerations. "Ultimately, how an implant case is treatment planned and executed should be determined by the patient's condition, input from all team members, and what the literature says is ideal for that situation," Brindis emphasizes.



**BIOTHREAD**  
Dental implant systems



**\$110 per implant**

**No contracts**

**Compatible with HIOSSEN**

**Built-in platform switch**



**Call us today!**

**1866-509-9685**

[www.biothreadimplants.com](http://www.biothreadimplants.com)



(Circle 22 on Reader Service Card)

Cement-retained restorations are thought to provide more esthetic options, especially in the esthetic zone, yet there is the problem of an increased potential for peri-implantitis from possible extravasation of cement into the peri-implant hard and soft tissues, Orentlicher explains. These issues can be overcome by utilizing a custom rather than standard abutment to keep the crown/abutment interface just below the gingival margin and by utilizing readily cleansable provisional cements rather than typical permanent cements, he says.

“Regarding screw-down restorations, unless ideal bone and soft tissue volume conditions are present and the implant platform position is good, achieving ideal esthetics in the anterior esthetic zone can be challenging,” Orentlicher elaborates. “In posterior regions, less-than-ideally placed implants can produce inappropriate screw access openings that can compromise cuspal anatomy and buccal and lingual integrity.”

Screw-down restorations can also have more potential mechanical problems with component and screw loosening or breakage, he adds. However, these restorations are usually more easily retrievable and don't present the problems associated with cement extravasation.

“As with most dental procedures, operator skill and meticulous execution are often more important than the specific technique,” Orentlicher advises.

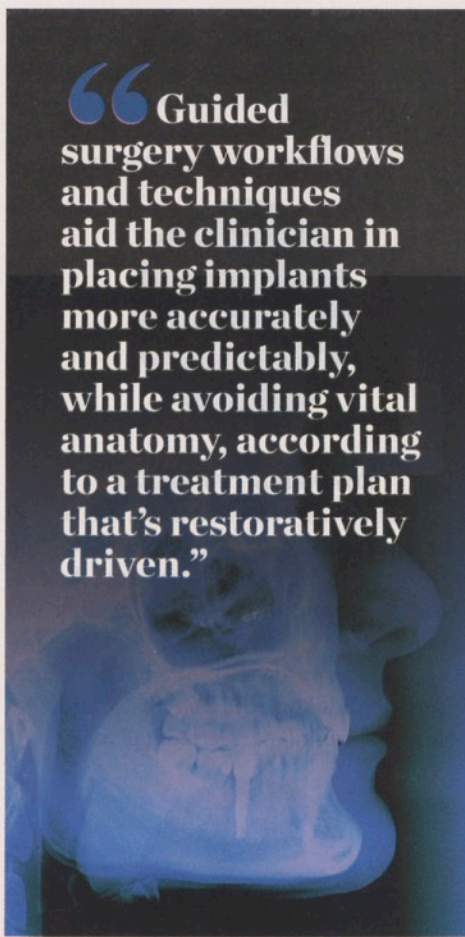According to Marais, it is imperative that strict protocols be followed with any screw-retained implant case. These include using stabilizing bars with custom open trays made from the preliminary models of close-tray impressions, performing a stone jig test on the master model to verify passivity, and incorporating long-term prototype restorations before proceeding to the definitive restorations. Using surgical guides for implant placement is also a must, he says.

## Embark with the End in Sight

Once upon a time, as long as osseointegration was achieved, dental implant treatment was considered successful. Nothing could be further from the truth, Gupta says, because osseointegration means nothing if the restorative result is embarrassing.

“Beginning with the end in mind is the only way to go, and it is getting very reliable as

“Guided surgery workflows and techniques aid the clinician in placing implants more accurately and predictably, while avoiding vital anatomy, according to a treatment plan that's restoratively driven.”



using digital technologies, such as the capability of merging intraoral scanning and CBCT files, becomes easier and more proficient,” observes Sesemann. “Digitally treatment planning cases can help the surgeon and restorative dentist communicate with great clarity, help the general dentist proceed responsibly, and make the prosthodontic procedures they are subsequently responsible for, easy.”

Prosthodontically-driven implant treatment planning begins by envisioning the tooth replacement in its position, Gupta explains. Whether a tooth is actually put on a model or drawn onto a panoramic radiograph, imagining the replacement tooth is the only way to determine ideal implant placement and angulation, he says.

“With anything in dentistry, we must have a goal in mind. If we don't take into account the restorative or ideal outcome, then we're never going to get there,” notes Duplantis, adding that it is extremely important to incorporate the laboratory into the planning process.

Large screw-retained, implant-splinted restorations are a good example, Marais says. “Poorly placed implants make the cementation of titanium bases into the structure a nightmare,” Marais has observed. “The laboratory technician will have to cement two or three at a time because the desired path of insertion was not possible. This also means that titanium bases and internal structures must be modified to achieve the desired path of insertion.”

However, CBCTs and other technologies enable patient information to be manipulated and applied to the implant treatment planning process so that the ideal implant location, position, and angulation, as well as the implant and abutment selection, restoration design, margin location, and tissue contours, can be determined precisely. By combining prosthetically driven needs with surgical needs, implants can be placed more accurately and restored in an efficient and predictable manner.

“I believe the primary driver for the expansion of prosthodontically-driven placement protocols and the increase of general dentist providers was the fact that there was a disconnect between the surgeon's placement of the implant without prosthodontic regard and the restorative dentist's nightmare experiences from having to restore an implant that was not prosthodontically-driven and, therefore, not optimally placed for efficient and optimal restoration,” Sesemann says. “Thankfully, the digital revolution is getting us all together on the same team, where we can work synergistically.”

## The Destination

Advancements in materials and technologies that enhance the predictability of dental implant procedures and techniques are enabling many general dentists to provide their patients with a new level of treatment and care. By undertaking credible education and training, understanding the essential factors that affect success, appropriately selecting cases, and properly planning treatment, general dentists can incorporate dental implants as a component of their practice. Whether they choose to both place and restore the implants themselves, or focus exclusively on providing the restoration and/or prosthesis, there's a place for dental implants in today's general practice.