The JOURNAL of Cosmetic Dentistry

The Official Journal of the American Academy of Cosmetic Dentistry®

In This Issue:

Accreditation Case Selection: The Direct Veneer Case

Bone Grafting at the Time of Extraction: A New Technique for Achieving Natural Bone and Tissue Contours in Esthetic Tooth Replacement

Benefits Beyond Beauty: A Perspective on Posterior Resin Restorations

Multiarch Vital Tooth Whitening Using a 15% Hydrogen Peroxide Gel Continuously Illuminated by a Gas Plasma Light Source

Rethinking the Cosmetic Dental Practice, Part IV: Overcoming Obstacles to Case Acceptance

The Art and Science of Behavioral Dentistry, Part I: Outcome, Means, and Prices

Volume 16 • Number 1
Spring 2000

accreditation case selection

The Direct Veneer Case

by Michael R. Sesemann, D.D.S.

Dr. Michael Sesemann graduated from the University of Nebraska Medical Center, College of Dentistry, in 1981. Dr. Sesemann and his staff founded the Nebraska Institute of Cosmetic Dentistry and specialize in comprehensive and esthetic dentistry. Dr. Sesemann looks forward to representing the AACD as the first dentist in the state of Nebraska to gain Accreditation. As an advocate of functional esthetic dentistry, he maintains a full-time practice in Omaha and lectures on the techniques necessary for successful completion of the comprehensive case.

INTRODUCTION

The following narrative is respectfully submitted in accordance with receipt of the grade of conditional pass for my Accreditation Review on June 9, 1998, in Vancouver, B.C., Canada. In light of the fact that my submitted case failed and my skills have evolved since performing that case in 1997, I have elected to submit a different case for review.

HISTORY

The patient was a 48-year-old woman in excellent physical health. The present condition of her oral health was also excellent. However, she had had extensive posterior restorative services rendered. For this reason, the patient was extremely sensitive to having anything invasive (a preparation procedure) done on her anterior teeth. Her wish was to have a more attractive smile presentation that would eliminate a midline diastema and the height/width inconsistencies of her six anterior teeth. In addition, a better proportional balance (the "Golden Rule") and more esthetically pleasing inclinations would help fulfill her objectives. The pretreatment appearance is illustrated in Figures 1, 3, and 5.

TREATMENT

The treatment consisted of direct bonding for the maxillary incisors and canines. The final result would be achieved without any preparation and thus would be fully reversible, for the patient's peace of mind. The gingival crest of the left central incisor was modified with electrosurgery at the time of composite placement. In accordance with a complete bonding protocol, the six maxillary anterior teeth were cleaned, etched, bonded, and restored with Renamel Microfill (Cosmedent; Chicago, IL) in three shades: A2, A1, and

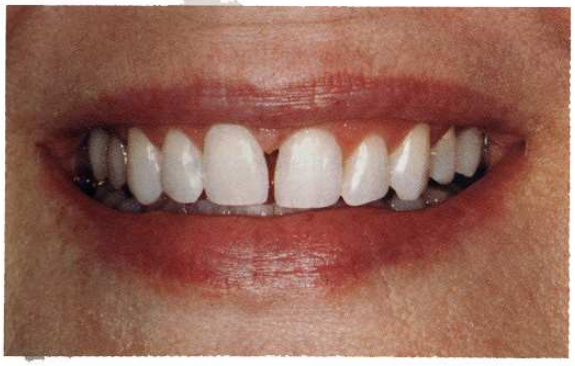

Figure 1: Smile, before treatment.

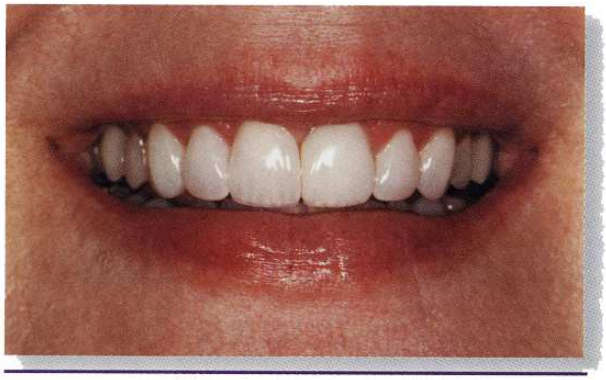

Figure 2: Smile, after treatment.

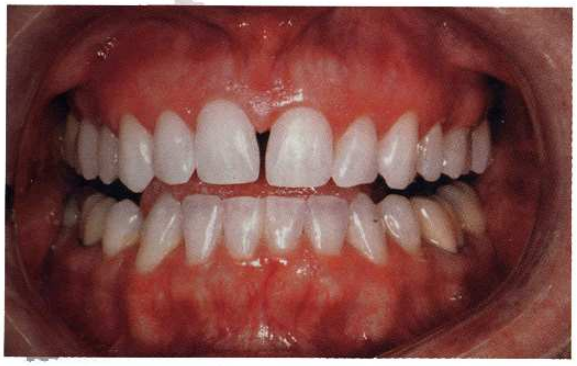

Figure 3: Retracted view, before treatment.

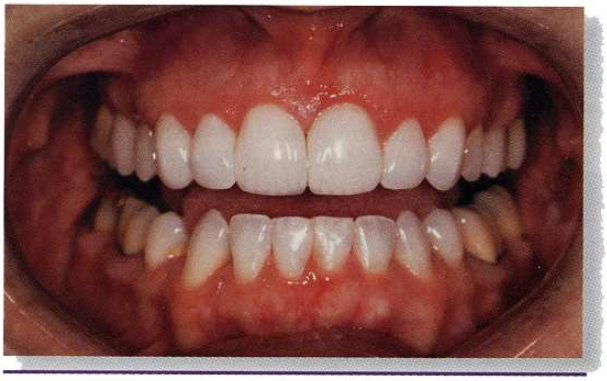

Figure 4: Retracted view, after treatment.

Figure 5: Six maxillary anterior teeth, before treatment.

Figure 6: Six maxillary anterior teeth, after treatment.

incisal light. The most difficult part of the composite placement was the shaping of the mesial subgingival contours of the central incisors in order to produce an emergence contour that would adequately support the central papilla and eliminate the diastema. The patient's appearance after direct veneer placement is shown in Figures 2, 4, and 6.

CONCLUSION

This patient's case was completed, from start to finish, in the 6 weeks before the San Antonio meeting. It was felt by prior examiners that this operator's previous case failed to exhibit the natural anatomic contours necessary for passage. My purpose in choosing a new case was to demonstrate the evolution of my skills related to direct bonded veneers by finding, diagnosing, and treating a patient within a condensed time frame. It is my hope that I have learned from my examination critiques and that this case is one that falls into the "zone of excellence" required for Accreditation.